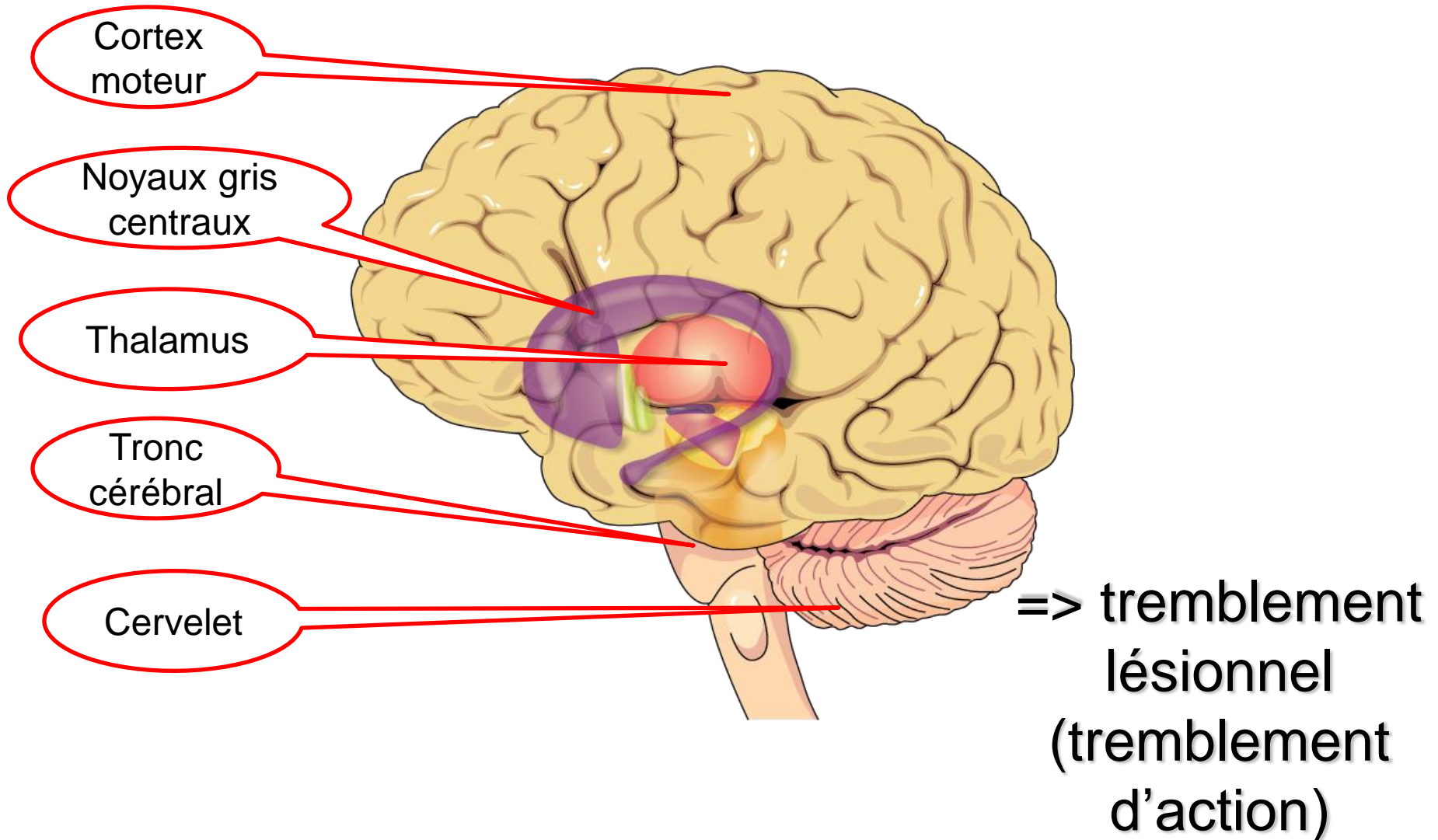


Tremblement et circuits moteurs



Physiopathologie
du tremblement:
Les lésions
cérébrales à
l'origine de
tremblements

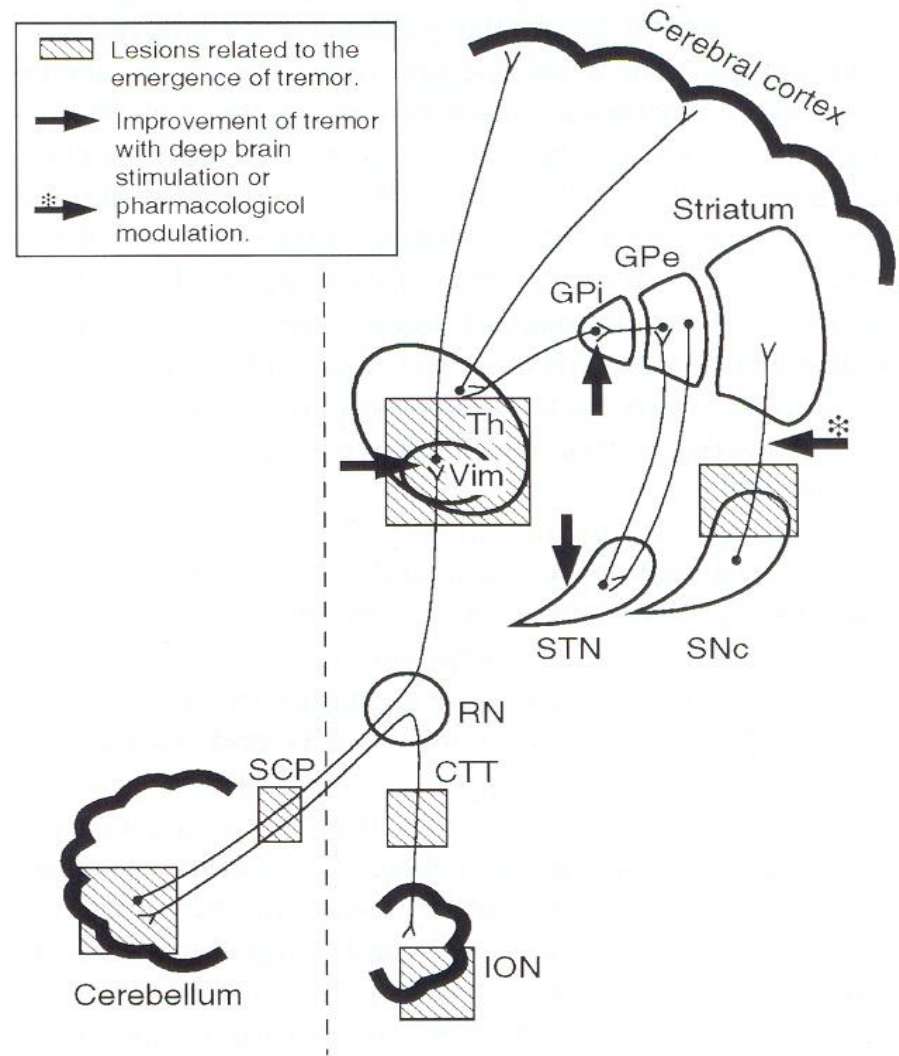
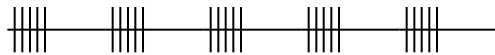
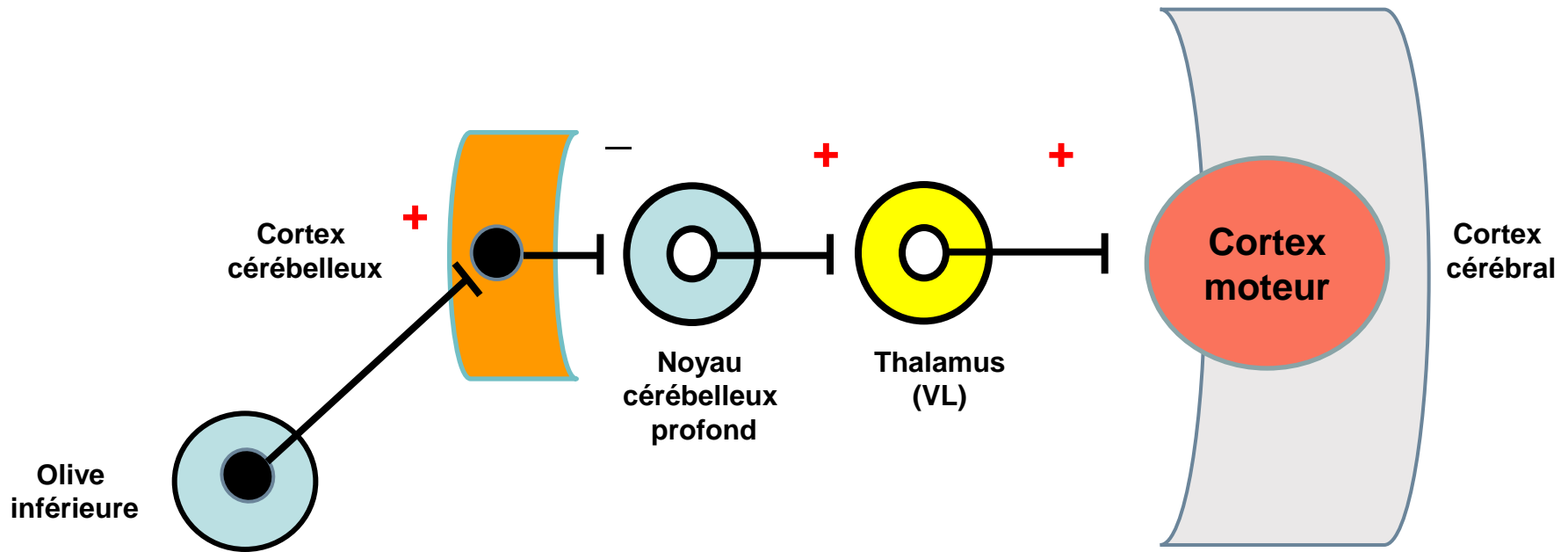
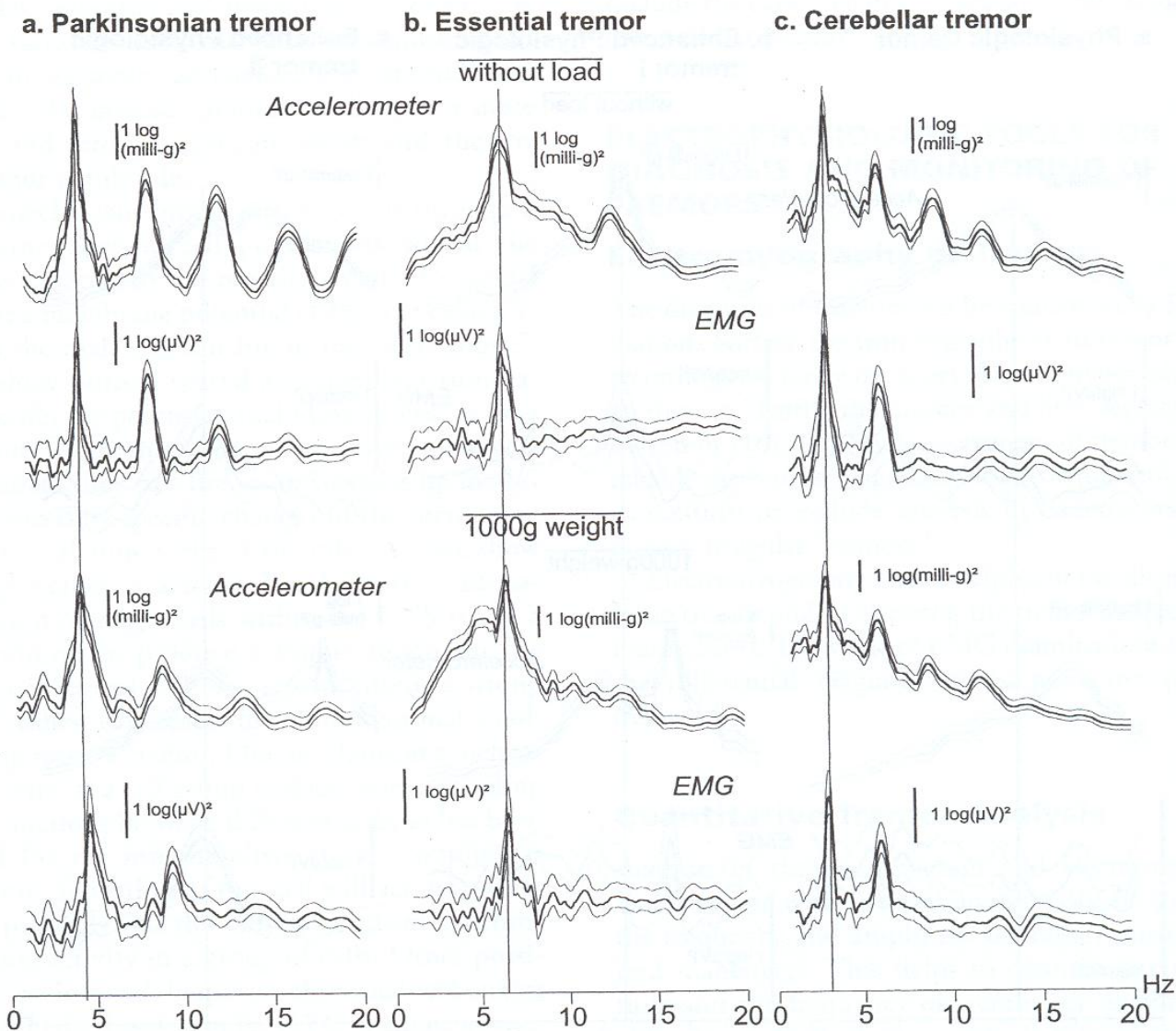


FIG. 3. Schematic representation of the pathways relevant to the pathophysiology of tremor.

Oscillateur central



Les trois principaux types de tremblement en dehors du tremblement physiologique



D'après:

G. Deuschl, J. Volkmann. Tremors: Differential diagnosis, pathophysiology, and therapy. In; Parkinson's disease and movement disorders. J. Jankovic and E. Tolosa Eds. 4th Edition. Lippincott Williams & Wilkins, Philadelphia, 2002, Ch 19, pp. 270-290